

### DEFINITION

A hernia is a prolapse of the membrane lining a cavity due to a defect in the wall of the cavity.

The abdominal cavity is the most common site, where the parietal peritoneal membrane herniates through a defect in the abdominal wall.

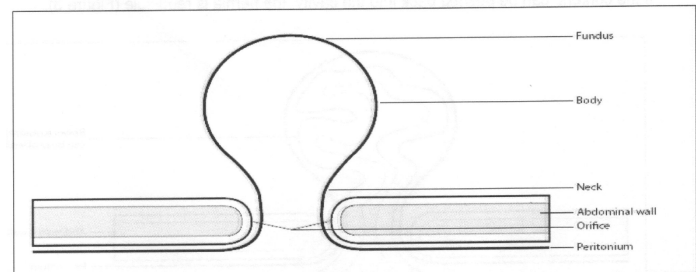
### EXAMPLES OF HERNIAS

- Indirect inguinal
- Direct inguinal
- Femoral
- Umbilical
- Para-umbilical
- Epigastric
- Ventral (incisional)
- Grynfeltt (superior lumbar)
- Petit (inferior lumbar)
- Spigelian
- Schwalbe
- Bochdalek
- Morgagni
- Hiatus

A pulsion diverticulum of the colon also meets the criteria of the above definition, that is, when the mucosa (lining of the cavity) herniates through a defect in the wall of the cavity (bowel wall). Zenker's diverticulum is another example.

### COMPONENTS OF A HERNIA

A hernia consists of a sack that has different parts (Figure 1), namely the ostium (mouth), neck, corpus (body) and fundus.

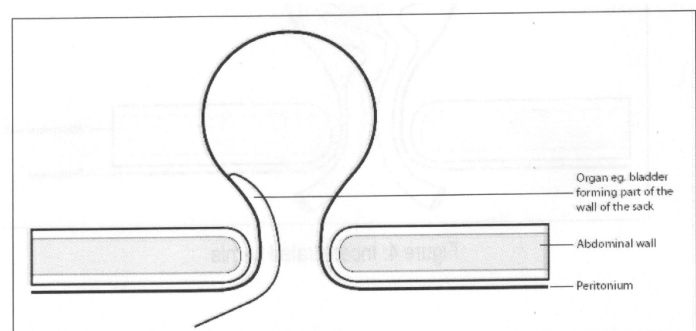


*Fig 1 Components of Hernia*

Clinically the hernia will protrude with raised intra-cavity pressure. The edge at the ostium can be palpated to assess the size and operability of the defect.

### Sliding hernia (Figure 2)

A hernia is referred to as a sliding hernia when part of the sack is an organ, usually the bladder, large bowel caecum in the right groin, sigmoid colon in the left groin and oesophagus in the hiatus of the diaphragm.

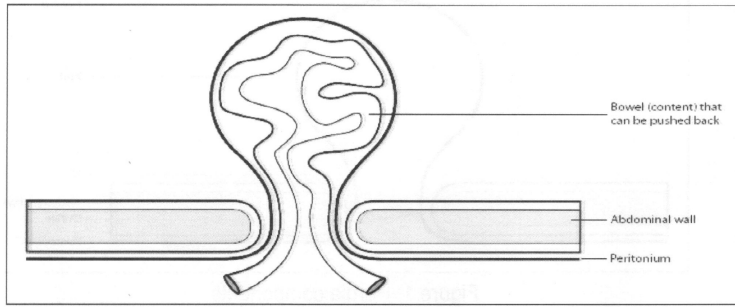


*Fig 2 Sliding Hernia*

### Content of the sack

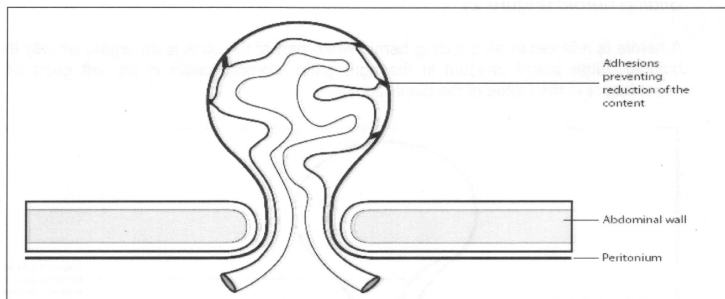
Any mobile organ (hollow or solid) in the cavity may enter the sack via the mouth and neck into the body of the hernia.

If the content can be pushed back into the cavity, the hernia is reducible (Figure 3).



*Figure 3: Reducible hernia*

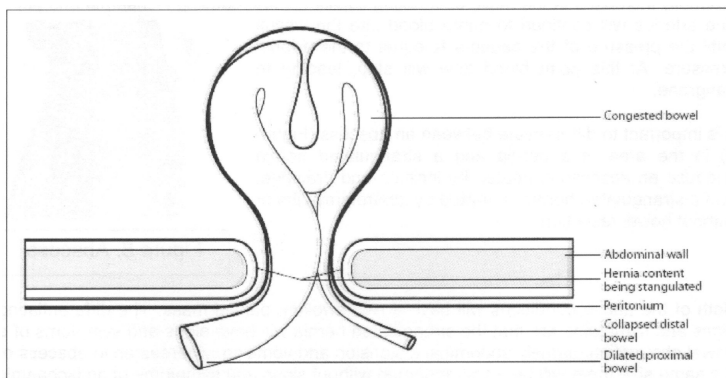
If the content (viscera) of the sack cannot be reduced for whatever reason, such as adhesions or an obturator, the content is incarcerated (imprisoned) (Figure 4).



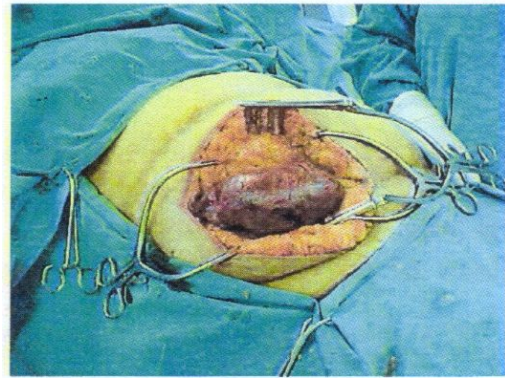
*Figure 4: Incarcerated hernia*

### **Strangulation**

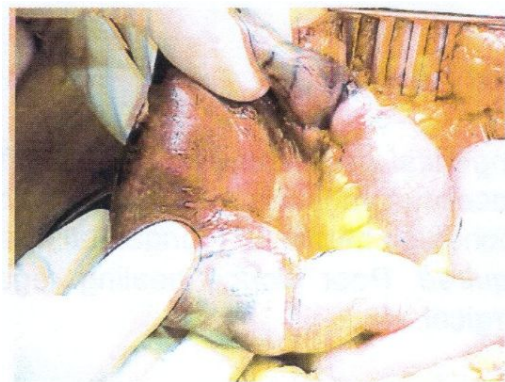When the blood supply to the viscera (content) in the sack is compromised, the viscus is strangulated and gangrene will set in (Figure 5, 6 and 7).



*Figure 5: Strangulated hernia*



*Figure 6: Strangulated inguinal hernia with gangrene*



*Figure 7: Strangulated inguinal hernia constriction rings clearly visible*

### **Pathogenesis of strangulation**

Increased pressure at the neck of the hernia first causes venous obstruction (low hydrostatic pressure). The arteries continue to pump blood into the organ, but there is no outflow, therefore oedema and congestion increase, causing "swelling". Pressure gradually increases at the neck, obstructing capillaries and causing ischaemia and pain. The arteries will continue to pump blood into the viscus until the pressure of the oedema is equal to the arterial pressure. At this point blood flow will stop, leading to gangrene.

It is important to differentiate between an abscess (Figure 8) in the area of a hernia and a strangulated hernia because an abscess is treated by incision and drainage, and a strangulated hernia is treated by laparotomy with or without

bowel resection.

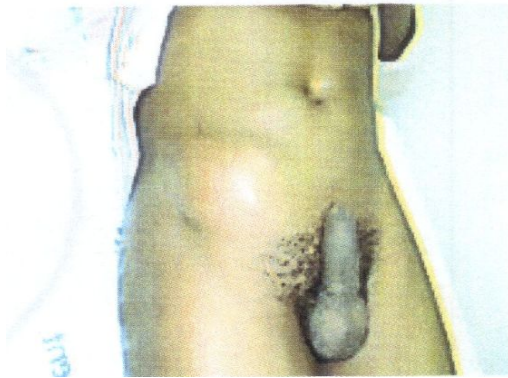

Figure 8: Abscess

Both of the above conditions will have a red, swollen, painful mass. The differentiating signs and symptoms are that the strangulated hernia will have signs and symptoms of a bowel obstruction, namely abdominal distension and vomiting, whereas an abscess of the same size there will be a soft abdomen without signs and symptoms of an ischaemic abdominal viscus.

## CAUSES OF HERNIAS

- **Congenital** developmental defect. This includes indirect inguinal hernia (patent processus vaginalis, umbilical hernia (failure of the umbilical orifice to close)) and Bochdalek hernia (congenital postero-lateral diaphragmatic defect).
- **Acquired.** Poor wound healing regardless of the cause, whether traumatic or surgical.
  - There are local and systemic causes:
  - Local causes: Poor surgical technique, ischaemia, tension, sepsis (Figure 9) or haematoma, etc.
  - Systemic: Smoking, malnutrition, diabetes mellitus, immune suppression (corticosteroids, chemotherapy), etc.

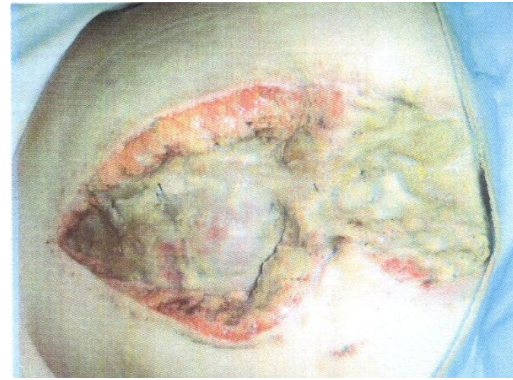

Figure 9 Sepsis

## INGUINAL HERNIA

Sixty per cent of indirect inguinal hernias, 25% of direct inguinal hernias, 15% of femoral hernias and 85% of groin hernias occur in men.

**Indirect inguinal hernia** (Figures 10 and 11).

This may occur at any age, with 1—3% in newborn babies and an incidence 30 times higher in pre-term babies. Indirect inguinal hernia is the groin hernia of young people, and the incidence tapers off after the age of 30.

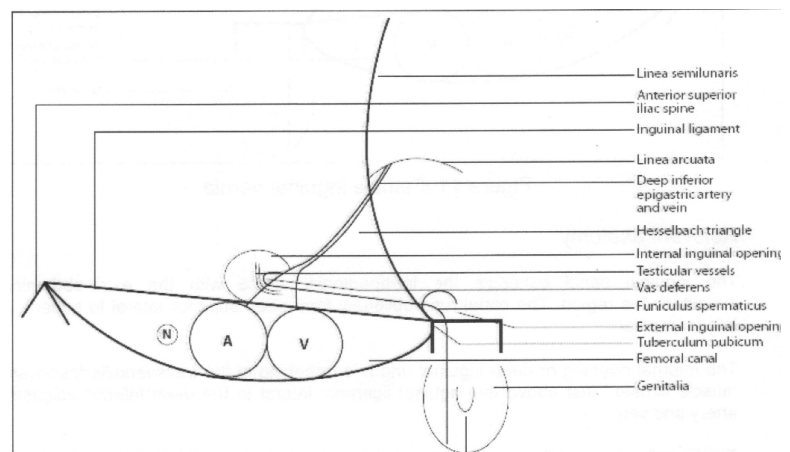


Figure 10: Male inguinal hernia

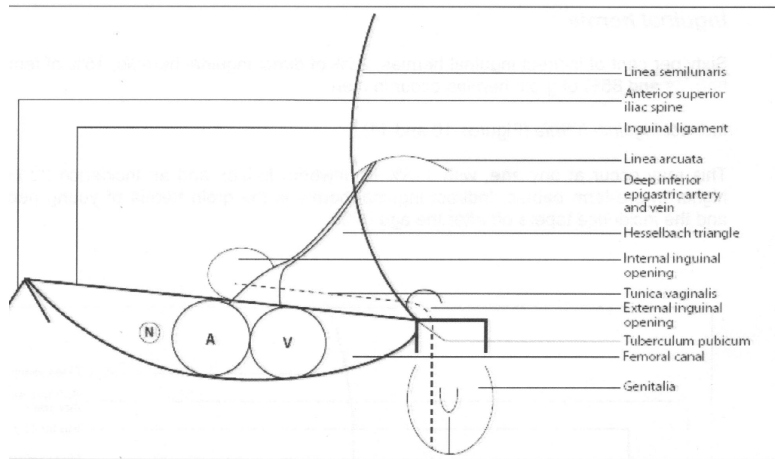


Figure 11: Female inguinal hernia

### Relevant anatomy

The inguinal canal connects the intraperitoneal space with the extra-abdominal subcutaneous region. The canal runs obliquely from deep superior lateral to superficial inferior medial. The internal opening or deep inguinal ring is an opening in the transversalis fascia and muscle situated just above the inguinal ligament lateral to the deep inferior epigastric artery and vein. To clinically close off the opening, the clinician simply feels for the femoral pulse in the groin and applies pressure above the inguinal ligament. This measure is necessary to control the content of the reduced indirect hernia. The external inguinal opening is superior and medial to the tuberculum pubicum. The funiculus spermaticus enters the internal opening and the content consists of:

- Testicular vessels, artery and vein (pampiniform plexus) descending from their origins high up near the kidney running along an extraperitoneal course to the internal opening.
- The vas deferens, running extraperitoneally from the verum montanum and crossing over the urethral external iliac artery and vein to its entrance at the deep inguinal ring. These structures curl around the outside border of the deep inferior epigastric vessels

(artery and vein) before entering the canal.

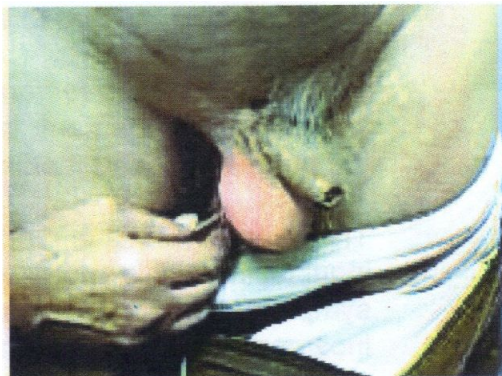- The tunica vaginalis (processus vaginalis), which is a narrow, elongated continuation of the peritoneum down to the scrotum. The tunica vaginalis, being a tubular structure, will have a lumen, and if obliterated, will have a potential lumen. This may open up again to form a hernia sack.
- Other structures forming the content of the funiculus spermaticus are lymphatic ducts.
- The inguinal canal is the region between the internal and external opening. The abdominal wall consists of layers of muscles (external, internal and transverse abdominal muscles). The inguinal canal takes an oblique course through these three layers. Each layer has an opening in it similar to three rugs lying on top of each other with openings lying obliquely next to each other, forming a cleverly designed shutter mechanism. In the case of a stoma (colostomy or ileostomy), the openings in the muscles lie on top of each other, and there is no shutter mechanism to absorb increased intra-abdominal pressure ~ this leads to a very high rate of stomal and para-stomal hernias.

The crurae of the external opening are fibres from the external oblique muscle of the abdomen. Traversing through this opening are the layers and content of the funiculus spermaticus. At the external opening the funiculus spermaticus is covered, from the outside in, by the external spermatic fascia (a continuation of the external oblique muscle) and the internal spermatic fascia (a continuation of the transversalis muscle). The degree of patency of the tunica vaginalis will determine what can enter into the hernia. If the canal is very small, as is the case in some congenital communicating hernias or in adults



with ascites or on peritoneal dialysis, it will only allow fluid to enter, giving rise to a communicating hydrocele. Transillumination (Figure 12) is the usual diagnostic method. If the opening or aperture of the tunica vaginalis is sufficiently large, it may allow any organ to enter and cause complications. Organs that may frequently be found are the small bowel, large bowel, bladder and omentum. Other rare organs are Meckle's diverticulum (Littre's hernia), the appendix (Amyand's hernia) or Richter's hernia, where only a part of the ante-mesenteric part of the bowel is stuck in the internal orifice.

Because the indirect inguinal hernia is a long narrow canal, it tends to have more frequent complications than other inguinal hernias, such as incarceration and strangulation.



*Figure 12 Trans-illumination*

### ***Direct inguinal hernia***

The direct inguinal hernia usually occurs in older people, unlike the indirect hernia, which can occur at any age, from a premature baby in an incubator to an old man in frail care in a nursing home. Direct hernias, on the other hand, are hernias through Hesselbach's triangle. This area is bordered by the lateral border consisting of the deep inferior epigastric vessels (arteries and veins), the inferior border consisting of the inguinal ligament, and the medial

border which is the lateral border of the rectus muscle.

The direct hernia, because of its anatomical position and the type of patient (older with weak tissue) who will get it, has a wide neck and is much shallower than the indirect hernia. It therefore seldom complicates (incarcerates or strangulates), although it does cause discomfort for the patient due to this weakness in the abdominal wall — it impairs the ability to increase intra-abdominal pressure at stooling or when lifting an object.

The direct hernia and the indirect hernia can occur simultaneously, and this is then called a pantaloon hernia, straddling the deep inferior epigastric vessels.

The direct hernia, because of its anatomical position, cannot descend into the scrotum because it does not have a potential space along which to dissect, as does the tunica vaginalis of the indirect hernia.

### **FEMORAL HERNIA**

The femoral hernia protrudes through the femoral canal which is situated medial to the femoral vein and dissects downwards inferior to the inguinal ligament into the upper thigh and later forward to exit through the fossa ovalis.

*The anatomy of the femoral canal* (Figures 8 and 9). The femoral canal is situated dorsal to the inguinal ligament, lateral to the lacunar ligament, ventral to Cooper's ligament on the pubic bone, and medial to the femoral vein.

The femoral hernia is more common in females. It must be kept in mind that the indirect inguinal hernia is more common than the femoral hernia, and if present it is usually symptomatic because it is a long, narrow canal that can easily cause symptoms due to incarceration and strangulation.

### Differences between indirect, direct and femoral inguinal (groin) hernias

| Indirect                                      | Direct                                       | Femoral                                       |
|---|--|---|
| Younger people<br>– present in all ages       | Older people                                 | Older people                                  |
| Predominantly male                            | Male or female                               | Predominantly female                          |
| May enter scrotum or labia                    | Cannot go down into scrotum                  | Present in thigh                              |
| Present along inguinal canal                  | Present in Hesselbach's triangle             | Present in femoral canal                      |
| Readily incarcerates and strangulates         | Seldom incarcerates and strangulates         | Readily incarcerates and strangulates         |
| Pathology is above inguinal ligament          | Pathology is above inguinal ligament         | Pathology is below inguinal ligament          |
| Reduction maintained by closing internal ring | With pressure on internal ring still present | Cannot be controlled by closing internal ring |

### UMBILICAL HERNIA

The umbilicus is the area in the foetus where the umbilical cord attaches to the abdominal wall. After birth, the cord remnant mummifies and falls off, and the abdominal wall skin attaches to the fascia of the linea alba. The skin of the umbilicus has no subcutaneous fat — when patients acquire excess fat, the umbilicus only gets deeper.

The umbilical orifice is a potential weak spot in the linea alba, which may give rise to an umbilical hernia.

In neonates and toddlers an umbilical hernia may be regarded as “normal” and will go away. In Caucasians this

occurs before the age of five years and in the negroid race it occurs before the age of seven years.

Indications for repair before these ages (five to seven years) are:

- Incarceration and strangulation (fortunately seldom).
- Size: a big orifice allowing two fingers to be inserted. A big orifice is less likely to close in time and the skin stretches to such an extent that cosmetic repair becomes difficult.
- After the age of five to seven years all diagnosed umbilical hernias need to be repaired.

### PARA-UMBILICAL HERNIA

This is a defect in the linea alba immediately above the umbilical orifice which will always include the umbilical orifice.

A para-umbilical hernia is a defect in the umbilical area where the skin covering the hernia sack is longer “above” than the skin of the lower part.

The diagnosis is clinical because, unlike in the case of umbilical hernias, para umbilical hernias do not close spontaneously and benefit from an immediate repair.

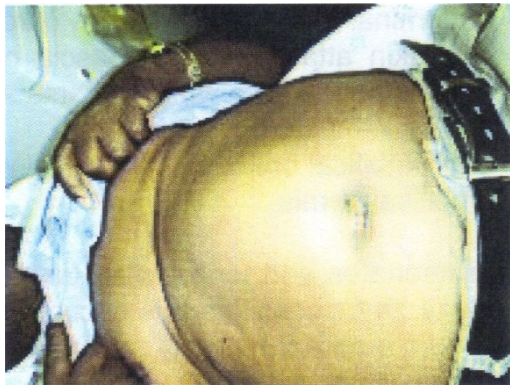### EPIGASTRIC HERNIA

This is usually a small defect in the linea alba (the size of an adult fingernail), with extraperitoneal fat herniating through the opening and causing pain when the rectus muscles are tensed.

Clinically it feels like a painful “marble” in the middle of the epigastrium. It will not go away spontaneously and needs to be repaired.

## DEVARICATION OF THE RECTUS SHEATH

The rectus muscles are in the midline and are wider apart than normal. The linea alba is wide and bulges outwards when intra-abdominal pressure is increased. Devarication of the rectus muscles is asymptomatic and does not need to be “repaired” when diagnosed. However, if it is present and the patient needs a midline laparotomy, then great care must be taken in the repair of the incision. It is the author’s impression that devarication of the rectus sheath predisposes ventral (incisional) and umbilical hernias to occur the rectus sheath



*Figure 13 Devarication of the rectus sheath*

## VENTRAL (INCISIONAL) HERNIA

This is a hernia that occurs in the same place as a previous surgical incision. There are local and systemic reasons for a surgical wound not to heal properly — the edges separate allowing the content of the cavity to herniate.

## HERNIA REPAIR

### Principles of repair

- The content of the hernia sack must be reduced back into the cavity. All adhesions either in the sack or against the abdominal wall must be released for the reduction.

- Excess sack must be removed and the remaining edge of the sac sutured closed at the neck.
- The edge rim of the defect in the wall needs to be closed, with due regard to the following:
  - The wall repair must be anatomical — the original anatomy must be restored to what it was and sutured in layers.
  - The sutures must be tension free.
  - If there is tension on the sutures and on the tissue, tension-releasing procedures are necessary, e.g. “Tanners slide” operation in inguinal hernia repair and “Ramirez” in ventral hernia repair.
  - The suture material must be as strong as the tissue being sutured (it does not need to be stronger).
  - Muscle should only be approximated, too-tight muscle sutures will cause ischaemia and will tear out.
  - Tendon or fascia may be used in the repair with the least chance of tearing out.
  - Non-absorbable mesh is currently being used to release tension and strengthen or buttress the repair.
  - The entrance and exit of the sutures should not be “in line”; this is to prevent the “postage stamp” effect, in other words “tearing along the perforations” (dotted line).
  - “Approximate, do not strangulate”. The latter happens so easily because the operators want to make sure that the suture is secure and tight, causing edge ischaemia, necrosis and recurrence.
  - Mesh placement.
    - Sublay
    - Inlay
    - Onlay

### **Sublay** (Figure 14)

Very specialised mesh such as Gore® Dual Mesh®, (Gore-Tex®), ProceedT™ mesh and Ethicon® with a protective

“visceral” layer must be used that may be placed against the viscera. The mesh may be placed on the bowel without the chance of it eroding into the bowel causing adhesions, sepsis, fistulation, increased recurrence, morbidity and mortality. Sublay technique is frequently used by laparoscopic surgeons where the content is cleared from the sack laparoscopically from inside. The specialised mesh is then placed on the inside of the abdominal cavity over the hernia opening in the wall. Ample overlap is essential. The mesh is stapled into position, thus completing the operation.

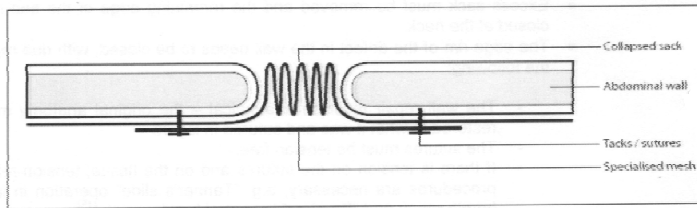


Figure 14: Sublay

#### Inlay (Figure 15)

Mesh is placed between the anatomical layers of the wall. The Lichtenstein tension free inguinal hernia repair or the inlay ventral hernia repair are good examples. The inlay hernia repair is the best, because it strengthens the wall, and by being integrated into the wall it causes fibrosis and scar tissue. The downside of the fibrosis is hardening of the area and less pliability, leading to impaired and sometimes painful movement.

Pre-peritoneal mesh inguinal hernia repair based on the “Stoppa”[16] principle is a favourite technique used by the author whenever possible, where ordinary mesh (without the specialised layers for bowel protection) is placed between the peritoneum and the abdominal wall overlapping the hernia opening and sutured in position.

The placement may be via the open or closed (laparoscopic) technique. The

open technique is preferred by the author because it is cheaper and does not need any specialised equipment. Access to the pre-peritoneal space in the open technique is through a lower abdominal midline incision. utuiecl ante

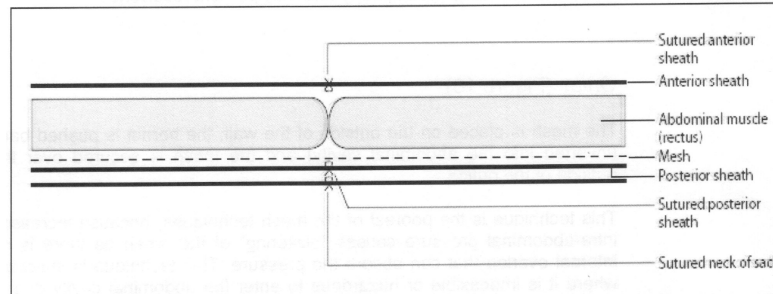


Figure 15: Inlay

In ventral hernia repair, the hernia sack is managed according to hernia repair principles (see above).

The edge of the hernia is incised, exposing the rectus abdominus muscle on both sides. Develop a plain between the muscle and the posterior sheath, suture the posterior sheath in continuity, place the mesh between the sutured posterior sheath and the rectus muscles, then suture the anterior sheath in continuity.

All the wounds are drained with a suction drain until the volume is 35 ml or less. A custom-made corset is fitted in theatre before the patient wakes up. The author believes that the counter-pressure provided by the corset:

- helps to prevent seroma formation
- assists with physiotherapy and may prevent recurrence.

#### Onlay (Figure 16).

The mesh is placed on the outside of the wall, the hernia is pushed back (inverted into the abdominal cavity) and the mesh is secured over the outside of the orifice.

This technique is the poorest of the mesh techniques, because increased intra abdominal pressure causes

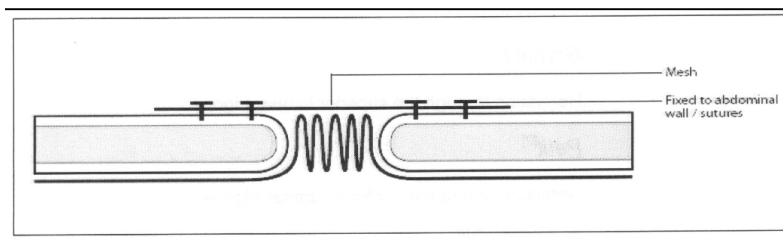


“blistering” of the mesh as there is no internal overlap that can absorb the pressure. This technique is indicated where it is impossible or hazardous to enter the abdominal cavity due to adhesions and scar tissue.

Under these hostile circumstances one simply needs to dissect out the sack down to the neck, push it back and secure the mesh over the orifice as best one can.



This work is licensed under a [Creative Commons Attribution 3.0 Unported License](https://creativecommons.org/licenses/by/3.0/).



*Figure 16: Onlay*

## **SPECIALISED HERNIA**

### ***Bochdalek***

Bochdalek congenital diaphragmatic hernia is a postero-lateral, pleuro-peritoneal defect presenting at birth with the classic signs and symptoms of central cyanosis, scaphoid abdomen and pectus excavatum. Diagnosis is confirmed with a chest x-ray.

Prognosis depends on the degree of pulmonary hypoplasia, determined by the time between birth and cyanosis. A short interval means a bad prognosis, and a longer interval means that there are enough alveoli to maintain life, except that the abdominal viscera in the chest impede function. This neonate has a good chance of survival if the content is removed from the chest and the hernia is repaired expeditiously by approximation of the edges with non-absorbable sutures or the placement of Gore® mesh to fill the defect.